

Case Report

Acute Myeloid Leukemia with Microfilaria: A Common Parasite with Rare Association in Eastern UP

Archana Bundela¹, Alpana Bundela²

¹Assistant Professor, ²Assistant Professor, Department of Pathology, BRD Medical College, Gorakhpur, Uttar Pradesh 273013, India.

Corresponding Author:

Alpana Bundela, Assistant Professor,
Department of Pathology, BRD Medical
College, Gorakhpur, Uttar Pradesh 273013,
India.

E-mail: archanaoctober79@gmail.com

Received on 21.08.2019,

Accepted on 12.10.2019

Abstract

Filariasis, a tropical parasite infection, caused by thread - like nematode, which is a common problem in the Indian sub-continent. Occurrence of filariasis with Acute Myeloid leukemia (AML) is unusual finding. Very few cases have been documented in literature so far. Here we report bancroftian filariasis in a male patient in association with Acute Myeloid Leukemia.

Keywords: Acute myeloid leukemia; Microfilariae.

How to cite this article:

Archana Bundela, Alpana Bundela. Acute Myeloid Leukemia with Microfilaria: A Common Parasite with Rare Association in Eastern UP. Indian J Pathol Res Pract. 2019;8(6):775-777.

Introduction

Filariasis can present with pyrexia lymphadenopathy or elephantiasis¹. Incidental finding of microfilaria in bone marrow aspirate is an uncommon finding and its association with hematological malignancy has rarely been described.² We describe case of filarial infection detected in peripheral and bone marrow smears when we were investigating for a suspected hematologic malignancy.

Case report

A 18 year old male patient, referred to department of pathology for Bone marrow examination with

indication of anemia. On examination, he was pale and febrile with mild splenomegaly. No lymphadenopathy was found. His Hemoglobin was 7.8 g/dl, total leukocyte count was 28,600/cumm, with a platelet count of 84,000/cumm. Differential leukocyte count on peripheral smear showed 22% blast and a sheathed microfilaria with somatic nucleus not reaching upto tail end was found. (Fig. 1) Bone marrow examination revealed a hypercellular smears with more than 65% blast. Many microfilaria were also seen in 2-3 bone marrow smears (Fig. 2). Blast were positive for myeloperoxidase stain (Fig. 3) confirmed a myeloid phenotype. A final diagnosis of Acute Myeloid Leukemia with Microfilaria was made and advised for cytogenetic study for further evaluation.

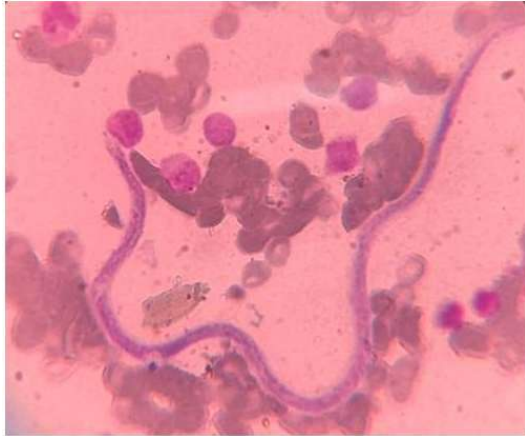

Fig. 1: Peripheral blood smear showing sheathed microfilariae with nuclei not reaching upto tail tip, suggesting it to be wuchereria bancrofti. Many blasts are seen adjacent to it (Leishman staining 100X)

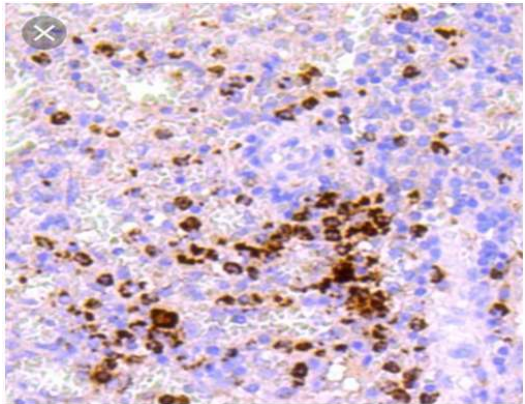


Fig. 2: Bone marrow smears are showing myeloperoxidase (MPO) positivity for blasts indicating acute myeloid leukemia

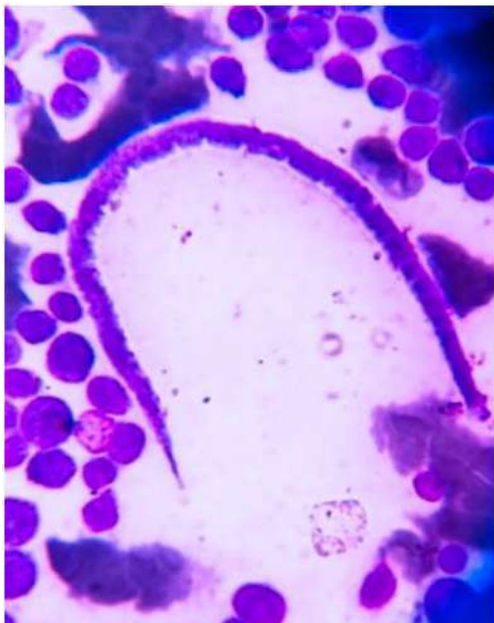

Fig. 3:

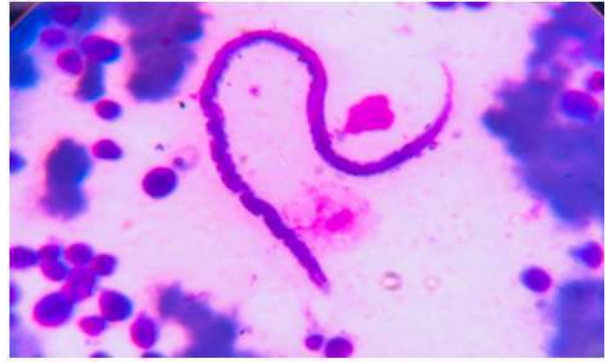

Fig. 4:

Fig. 3,4: bone marrow smear showing sheathed microfilariae with nuclei not reaching upto tail tip, suggesting it to be wuchereria bancrofti. Many blasts are seen adjacent to it (Leishman staining 100X)

Discussion

Filariasis has been known from antiquity. Microfilaria was first observed by Demarquay (1863) in hydrocoel fluid and genus is named after Wucherer. In 1878, Bancroft first reported and described adult female worm and adult male worm was described by Bourne.

W. Bancrofti is distributed widely in the tropics and subtropics of sub-Saharan Africa, South-East Asia, India and Pacific Islands. The largest number of cases occurs in India.³

W. Bancrofti is the most wide spread of filarial nematode infecting humans. Mosquito species belonging to the anopheles, culex, Aedes, Mansonia, are carriers of lymphatic filariasis.⁴

Filarial infection may be associated with any benign and malignant condition, even when not suspected clinically.⁵ Incidental finding of microfilaria in peripheral and bone marrow smears having AML was similar to findings described by Rahman K *et al.*⁶ in 2012, Microfilaria with AML and a second case that described by Sharma *et al.*⁷ in 2010 was AML-M4 with eosinophilia and third by Sonal Jain *et al.*⁵ in 2011, a case of B-ALL.

This present case is very unique as here microfilariae have been reported in bone marrow smears, which was primarily aspirated to rule out leukemia. Adult worm reside in lymphatic vessels and the larval form (microfilariae) may circulate in peripheral blood. however in literature it has been described in aspirate from thyroid, soft tissue, lung, epididymis, bonemarrow, bronchoalveolar fluid hydrocoel fluid, breast, gastric brushing and subcutaneous swellings.⁸

Conclusion

There are few case reports demonstrating the association of filariasis with hematological malignancies, however our case, AML with filariasis is the first to be reported in Eastern UP. Hence it is concluded that in endemic areas, the possibility of microfilaria should be kept in mind in patient with fever, even in the absence of classical clinical presentation and peripheral and bone marrow smears should be screened with a high index of suspicion.

Careful evaluation of smears not only reveals the primary pathology but also coincidental pathology.

References

1. Gupta S, Gupta R, Bansal B, *et al.* Significance of incidental detection of filariasis on aspiration smears; a case series. *Diagn Cytopathol.* 2010 Jul;38(7):517-20.
2. Pradhan S, Lahiri VL, Ethence BR, Singh KN. Microfilariae of *Wuchereria bancrofti* in bone marrow smear. *Am J Trop Med Hyg.* 1976;25(1): 199-200.
3. Kinger M, Chakrabarti PR, Sharma S, *et al.* Unusual case of bancroftian filariasis co-existing with chronic myeloid leukemia. *Ann Trop Med Public Health* 2014;7:64-6.
4. Nwoke BE, Nwokke EA, Ukaga CN, *et al.* Epidemiological characteristics of Bancroftian filariasis and the Nigerian environment *J Public Health Epidemiol.* 2010;2:113-7.
5. Jain S, Dass J, Sharma M, *et al* Common parasite with uncommon association. *Mediterr J Hematol Infect Dis.* 2011;3:e2011015, doi:10.4084/mjhid.2011/05.
6. Rahman K, George S, Sardana M, *et al.* Microfilaria with Acute Myeloid Leukemia: A Common parasite with Uncommon Association. *Indian J Hematol Blood Transfus* 2013 Jun;29(2):113-15. doi 10.1007/s12288-012-0154y.
7. Sharma P, Tyagi S. An unusual cause of eosinophilia in AML - M4 without the inv (16) abnormality. *J Blood Disord Transfus.* 2010;1:104
8. Arundhati Kumar A, Kumar R, Acute lymphoblastic leukemia with microfilaria: A rare coincidence in bone marrow aspirate *Indian J Hematol Blood Transfus.* 2011;27:111-2.